

Cross linking in età pediatrica: caso clinico

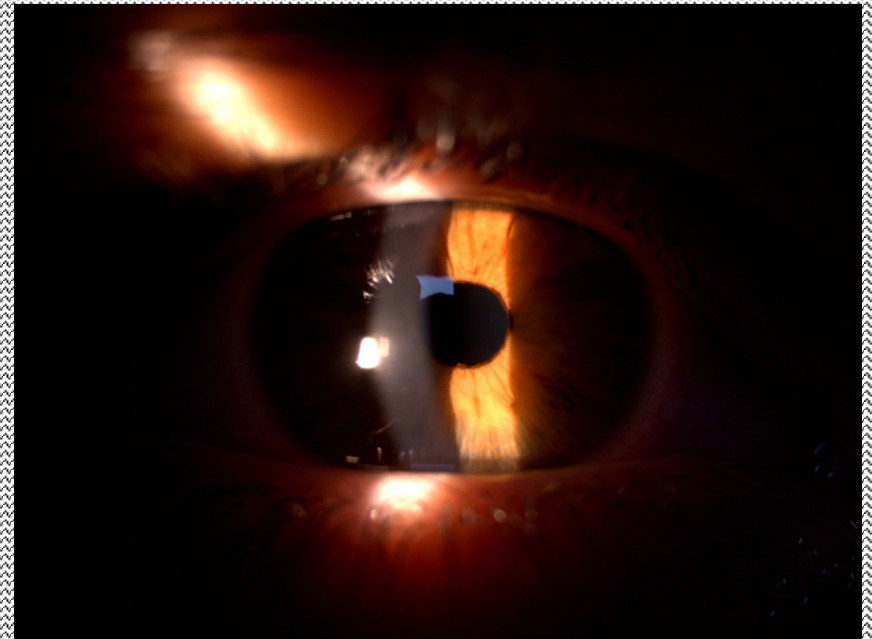
Bologna, 25 Settembre 2012

Luca Avoni

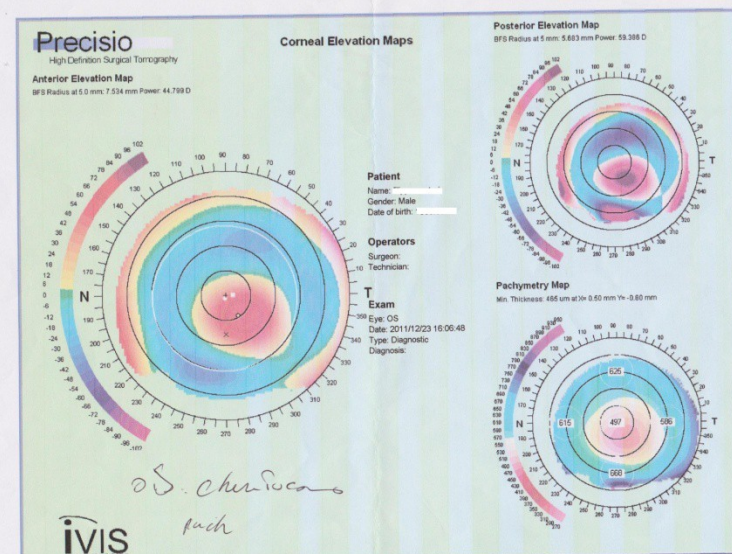
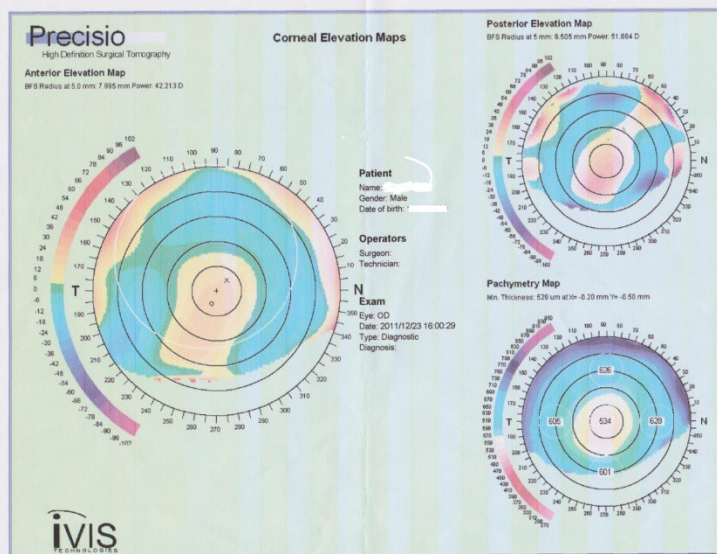
Ospedale Maggiore di Bologna
Banca delle Cornee dell'Emilia
Romagna

Introduzione

- Paziente di 12 anni
- Recatosi per effettuare una visita oculistica per calo del visus nel Settembre 2011
- Vod: 9/10 nmcl
- Vos: 2/10 nmcl
- Boo: cornea trasparente
- Richiesta una topografia corneale



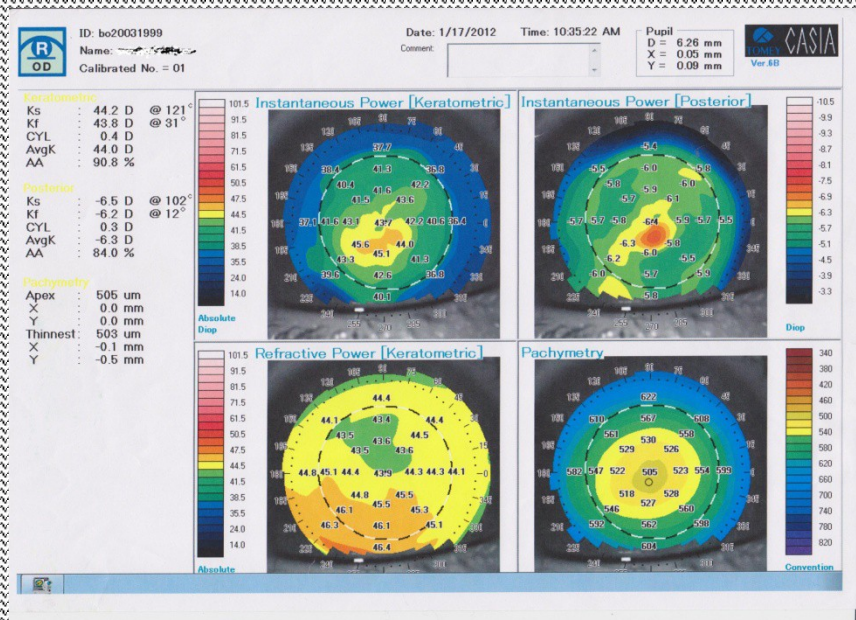
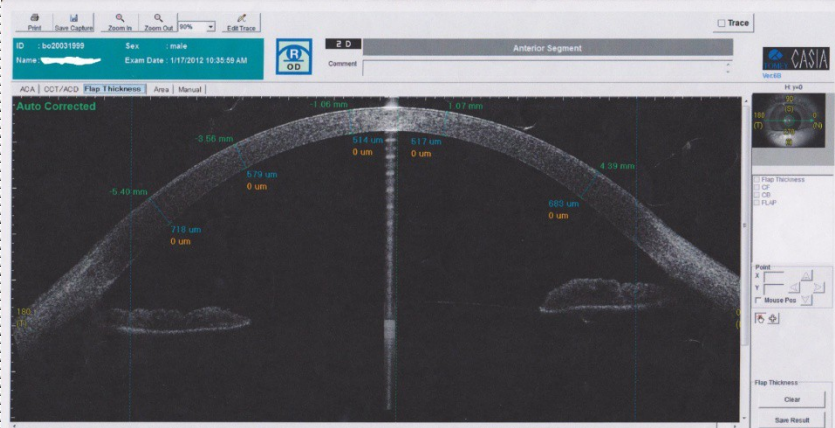Cheratocono



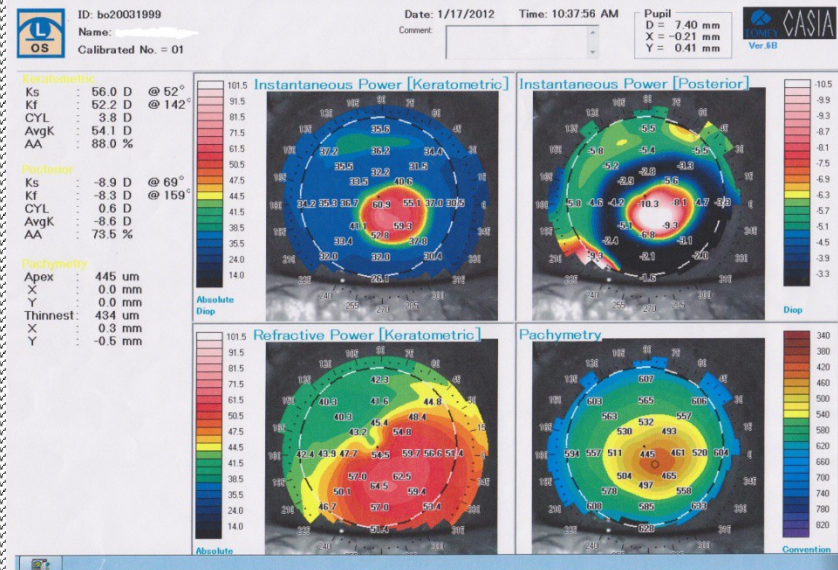
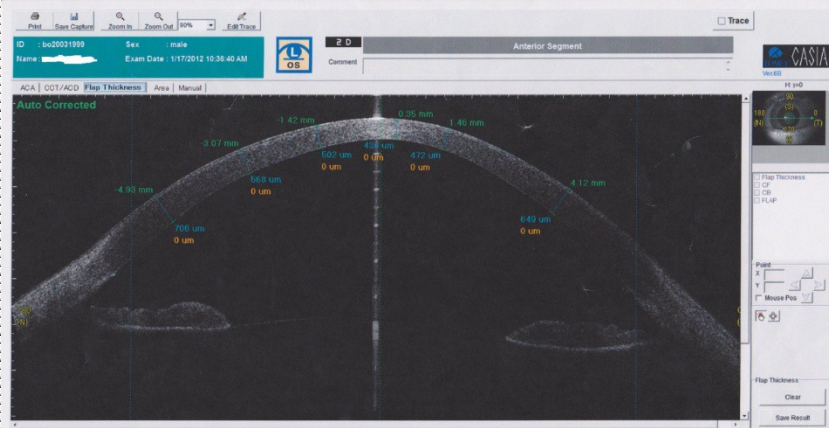
Gennaio 2012

- Giunge alla nostra osservazione
- Situazione clinica vod:9/10nmcl vos:2/10 nmcl
boo:cheratocono cornea trasparente
- Si effettua un CASIA

OD:PRE CROSS LINKING



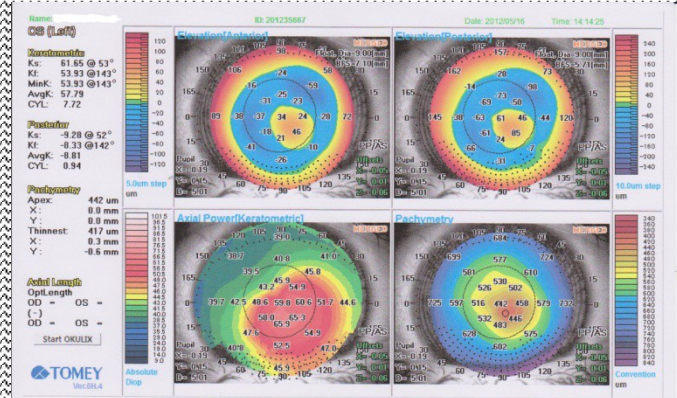
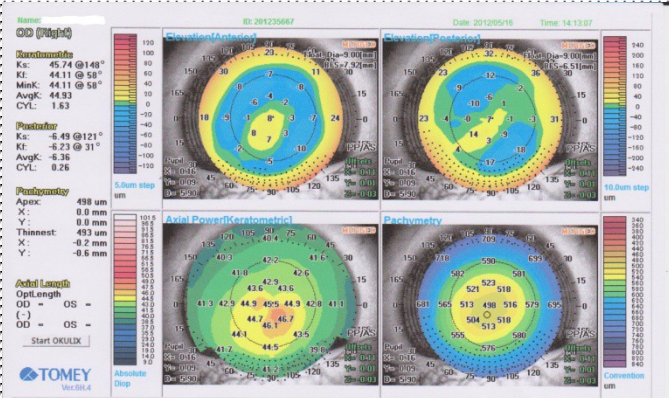
OS:PRE CROSS LINKING



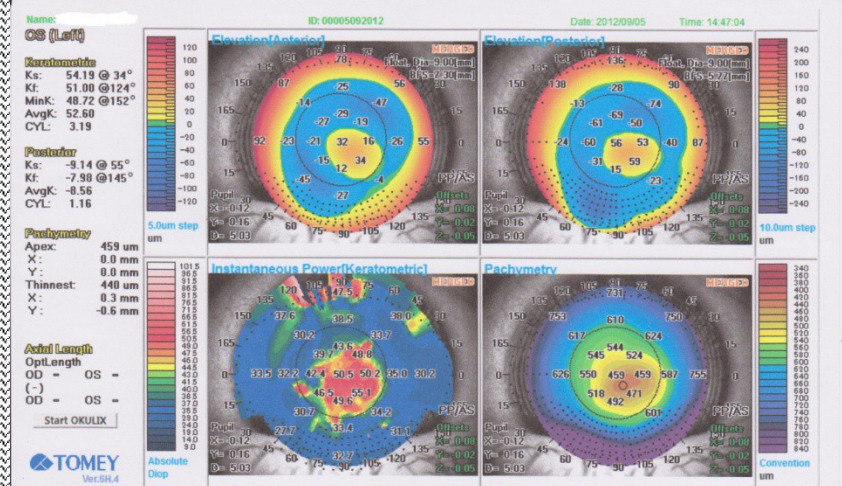
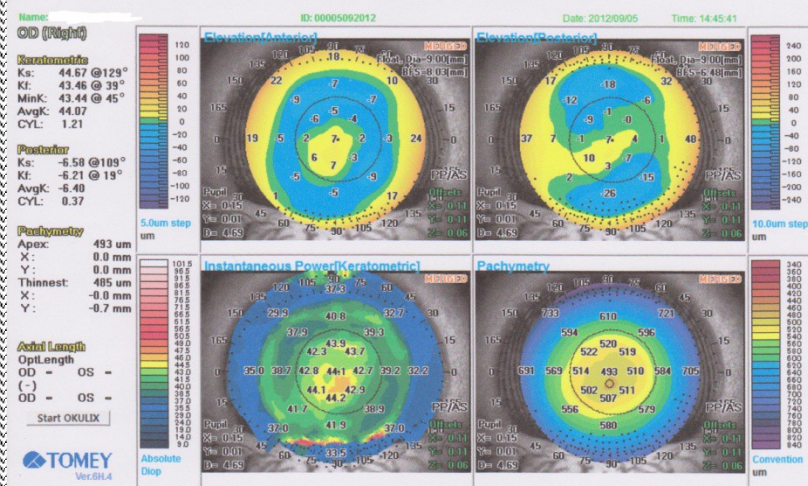
INTERVENTO

- Os:cross linking Febbraio 2012
- Od: cross linking Marzo 2012

Post cross linking a 3 mesi

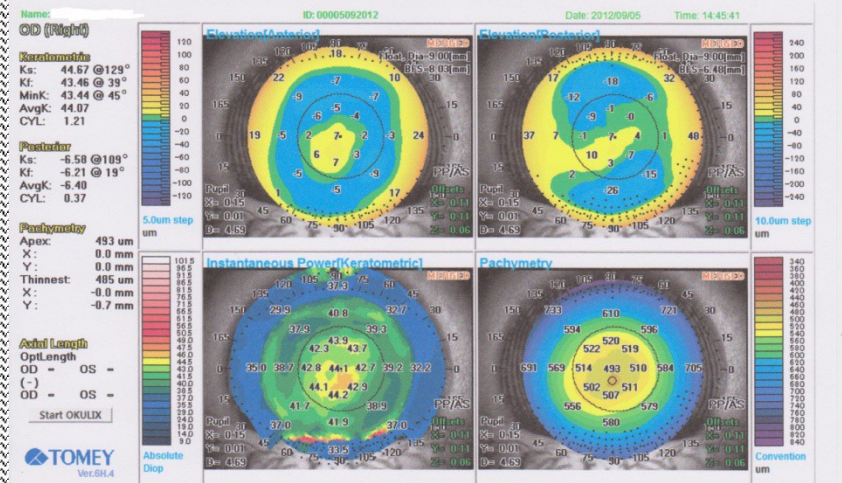
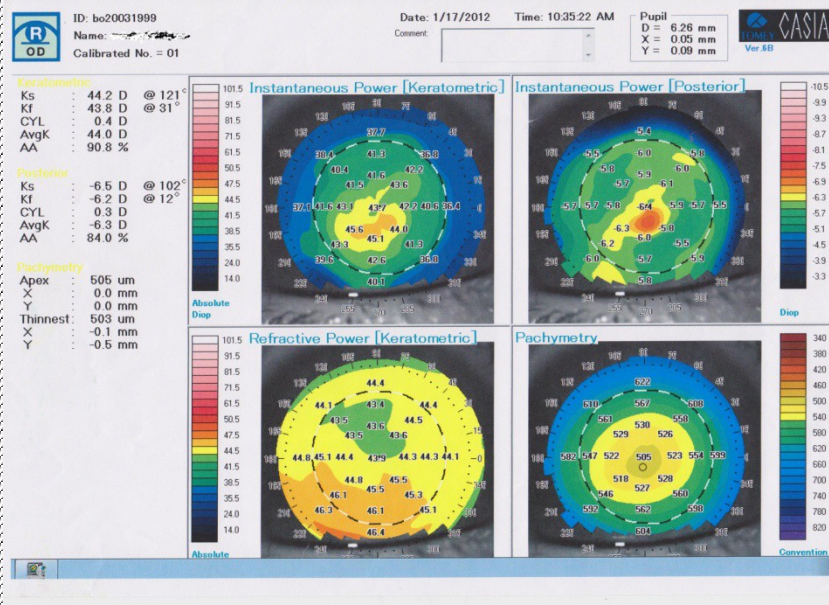


Risultato a 6 mesi post cross linking



PRE E POST OPERATORIO OD

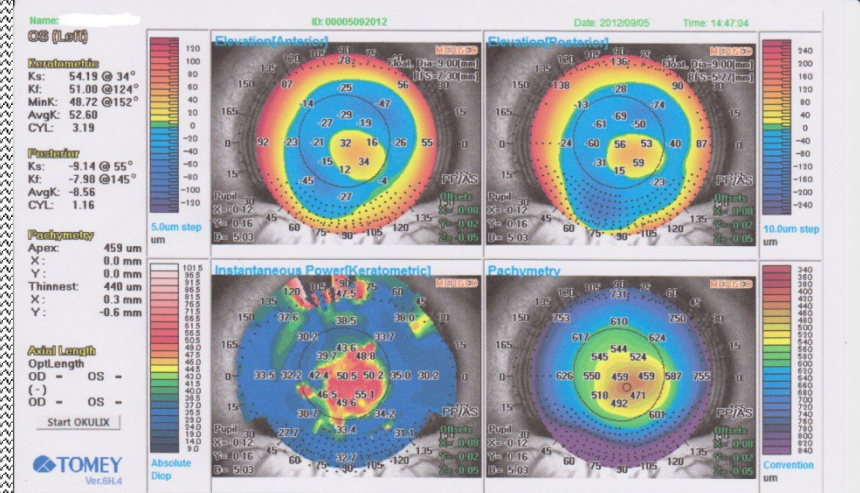
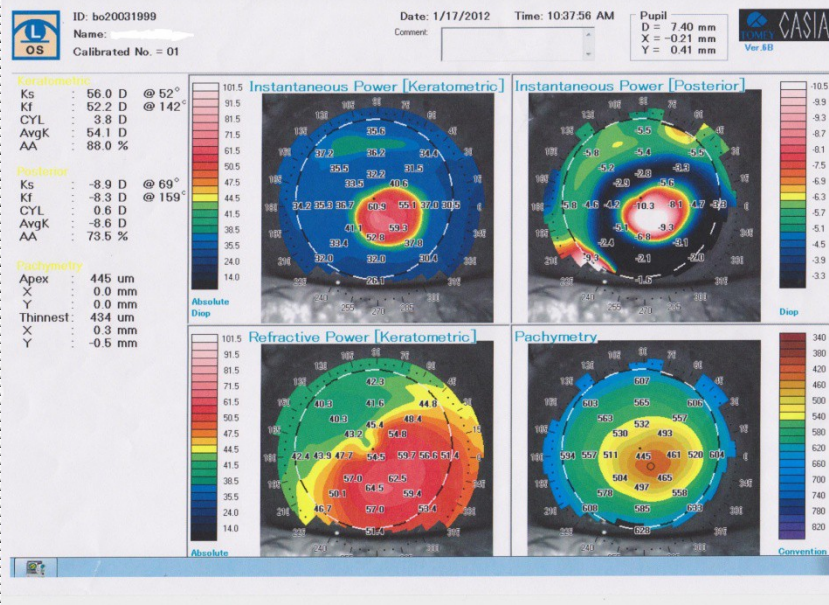
- Pre cross linking
- Post a 6 mesi



PRE E POST OPERATORIO OS

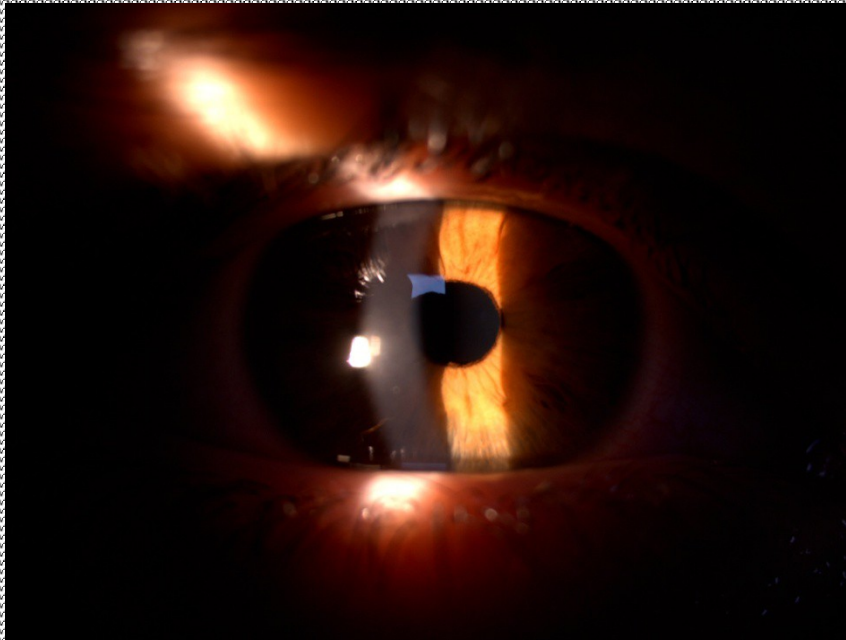
• Pre cross linking

• Post a 6 mesi



Lenti a contatto post cross linking

- Contattologia morbida



- Contattologia morbida e rigida associate



A 6 mesi

- Vod:9/10 nat 10/10 con lac
- Vos:2/10 nat 10/10 (4 lettere su 5) con lac
- Boo:cornea trasparente
- Cheratocono stabile
- Paziente tollera bene le lenti a contatto ed è soddisfatto del visus
- Nei primi due mesi riferiva un calo qualitativo del visus od

Grazie per l'attenzione

